

Title: Diastema closure in anterior teeth using a posterior matrix

Authors-

- 1) Dr. Ayush Goyal
Lecturer
Dept. Of Conservative Dentistry & Endodontics
Subharti Dental College
Meerut, Uttar Pradesh, India.
Email ID: ayush2106.goyal@gmail.com

- 2) Dr. Vineeta Nikhil
Professor and Head
Dept. Of Conservative Dentistry & Endodontics
Subharti Dental College
Meerut, Uttar Pradesh, India.
Email ID: drvineeta_dav@rediffmail.com

- 3) Dr. Ritu Singh
Lecturer
Dept. Of Paediatric and Preventive Dentistry
Subharti Dental College
Meerut, Uttar Pradesh, India.
Email ID: ritusingh87@gmail.com

Abstract

Presence of diastema between anterior teeth is often considered an onerous esthetic problem. Various treatment modalities are available for diastema closure. However, not all diastemas can be treated the same in terms of modality or timing. The extent and the etiology of the diastema must be properly evaluated. Proper case selection is of paramount importance for a successful treatment. In this case report, diastema closure was performed with direct composite restorations. One bottle etch-and-rinse adhesive was used and a single shade was used to close the diastemas. Contoured sectional posterior matrix was used to achieve anatomic contouring of the proximal surfaces of the teeth. This was followed by finishing and polishing using polishing discs. Patient was kept on recall every 6 months.

Conclusion: Diastema closure with correct anatomic contouring is easy to perform using the contoured sectional matrices. At 14-month recall, no clinical signs of failure like discoloration or fracture were evident. Also, patient did not complain of any sensitivity. Thus, direct composite restorations serve as durable and highly esthetic restorations leading to complete patient satisfaction.

Keywords: Diastema closure, Posterior matrix, Palodent matrices

Diastema closure in anterior teeth using a posterior matrix

Introduction

Midline diastema is defined as anterior midline spacing greater than 0.5 mm between the proximal surfaces of central incisors [1]. It has been reported that maxilla has a higher prevalence of midline diastema than mandible [2]. Midline diastema is multifactorial in etiology. Some of the causes include: maxillary incisor proclination, labial frenum, incomplete coalescence of the interdental septum, pseudo-microdontia, presence of a mesiodens, peg-shaped lateral incisors, congenital absence of lateral incisors, pathologies (e.g. cysts in the midline region), habits such as finger sucking, tongue thrusting, and/or lip sucking, discrepancy in the dental and skeletal parameters and probably genetics [3].

Once the etiology is known, a decision must then be taken whether to utilize a multidisciplinary approach or to simply close the spaces by means of direct and/or indirect restorative treatment. If the teeth are correctly aligned and positioned, but the tooth size is the culprit, the clinician is left with the task of selecting the best restorative procedure [4, 5].

Recent aesthetic composite resin materials offer a diverse range of shades and varying opacities designed specifically for layering technique [6, 7].

Creating an anatomic contour without “black triangles” is an arduous task when closing diastemas using resin-based composites. This case report describes diastema closure in the maxillary anterior region using resin-based composite material with the help of stainless steel pre-contoured matrices.

Case Report

A 52-year-old male patient reported to the department of Conservative Dentistry and Endodontics, Subharti Dental College with a chief complaint of spacing in his upper front teeth region. Patient's medical history was non-contributory and intraoral examination using a Vernier Caliper (Aerospace Digital Vernier Caliper, India) revealed interdental spacing between maxillary central incisors (~4 mm) and maxillary central and lateral incisors (~1.5 mm) (Fig. 1 to Fig. 3). No dental caries were observed upon both clinical and radiographic examinations.

Among the different treatment options for this case, we selected the most conservative because of patient's desire for quick results and his financial constraints. Also, though not a regular visitor to the dentist, the patient demonstrated good oral health.

Before starting the treatment, preoperative photographs (Nikon® Coolpix L810) were taken. Following oral prophylaxis, shade selection was done using the VITAPAN® Classical Shade guide (A2) and an intraoral mock-up was done with A2B shade of Filtek™ Supreme XT (3 M/ESPE, St. Paul, MN, USA). Once the patient was satisfied, it was decided that only a single shade (A2B) would be used to close the all the diastemas. The midline diastema was closed by building up the mesial surfaces of central incisors one by one. It was decided to restore 21 first. No tooth preparation is necessary prior to adhesive procedures. 37% phosphoric acid (Etching Gel, Kerr, USA) was applied on the mesial surface for 15 seconds, rinsed for 20 seconds, and slightly air-dried. It is advisable to etch a little more surface area (labial) as the exact

location of final restoration margin is uncertain [8]. Then, two coats of a single bottle bonding agent (Adper Single Bond, 3M ESPE, USA) were applied using applicator tips and polymerized for 20 seconds with an LED light (Elipar™ 2500, 3M ESPE Dental products, US). Care was taken to apply uniform coats of the bonding agent especially near the gingival area.

Following this, a small increment was placed near the “future” contact area and manually contoured over the mesial surface using a long bladed titanium instrument (Fig. 4a and 4b). The composite was then sculpted beneath the free gingival margin and shaped to ideal contours. A brush was then used to thin the material to obtain an imperceptible margin (Fig. 4c). The increment was cured with LED light for 40 seconds, both from labial and palatal aspects. Then, a contoured sectional matrix (The Palodent® System, DENTSPLY Caulk, Milford, Delaware, US) was placed on the mesial surface of 21 with one end slightly into the sulcus (Fig. 5). This is to assure the progressive emergence profile of the resin composite. This contoured matrix was then stabilized by holding it from the palatal side and resin composite was then added incrementally to complete the build-up of 21. These contoured matrices are much rigid (unlike mylar strip) which confers them some degree of self-stability. A mylar strip can be placed on the palatal aspect to act as a frame against which to pack composite (Fig. 5). Although, some clinicians prefer a gloved finger for this purpose. Each increment was cured for 40 seconds from both labial and palatal aspects.

The same procedure was repeated for 11 (Fig. 6 and Fig. 7). Care should be taken to place the matrix slightly into the sulcus (Fig. 6). Placing and stabilizing sectional matrix in 11 would be much simpler as the mesial surface of 21 would provide it with a “positive stop”. Once the midline diastema was restored, the diastema between central and lateral incisors was closed in the same manner. Final finishing and polishing was accomplished with Sof-Lex discs (3M ESPE Dental Products. St. Paul, MN. USA). The incisal embrasures were kept small and general anatomic forms of teeth were kept flat and broad which best suited his face and body type (see flat canines of the patient). No or minimal characterization was given on the labial aspects of the teeth. Final outcome of the restorative procedure can be seen in Fig. 8 and Fig. 9.

Once all the restorations were placed, the occlusion was verified in both centric and eccentric relations using an articulating paper.

The patient was motivated for oral hygiene and informed for recalls. After 6 months, the restorations were only polished using Sof-Lex discs. The patient was recalled after another 6 months. However, he could not return until 8 months. At 14-month recall (Fig. 10), the restorations were evaluated according to modified United States Public Health Service (USPHS) criteria [9]. The scores for all the test procedures were found to be A (Alpha).

DISCUSSION

Resin-based composite restorations are single-visit procedures and bypass laboratory work which reduces cost of the treatment. They usually do not require wax-ups and preliminary models. In addition to this, some added advantages that these restorations have over other common treatment modalities are- a) they are gentle towards the opposing dentition, unlike ceramic materials and b) they are easy to repair in case of fracture. With porcelain restorations, any modification means a return-trip to the laboratory for correction [10, 11].

However, there are some distinct disadvantages that these restorations possess which makes case selection critical. Composite restorations possess less color stability compared to ceramics. This, of course is related to the degree and quality of polishing, but also depends on the patient maintenance [12]. Our patient demonstrated good oral hygiene and was given further instructions regarding the same. Secondly, they possess less fracture toughness, compressive and shear strength and hence are not suited for high-stress bearing areas [13].

In spite of these disadvantages, the clinicians have been offered with the best quality resin materials today which allow them to yield esthetic, functional, economical and durable restorations. We chose to close the diastema using composite restorative material because it was the most conservative treatment possible, the patient exhibited good periodontal health and also because the patient was not willing for an expensive treatment. Excellent outcomes have been reported by numerous authors who have used resin composites for diastema closures [14-16].

Mesial anatomic contouring could be easily achieved because of the inherent shape of the matrices. One of the biggest challenges that the clinicians face is the failure to avoid “black triangles” when closing diastemas. The restorative technique described here can be applied with relative ease to avoid the “black triangles”.

These matrices are especially useful in cases where large diastemas (3-4 mm) have to be closed using direct composite resin restorations. The matrices used in this case are polished stainless steel matrices intended for single use only. Since they are polished and made of “soft” metal, there is no risk of epithelial damage when passively inserted into the sulcus. The manufactures recommend steam autoclaving the matrices at 134°C for 3 minutes prior to clinical use. Unlike the BiTine® rings which can be autoclaved 700 times, the matrices can be autoclaved only once [17].

Although use of rubber dam is said to be of paramount importance in placing composite restorations, it was decided to use cotton-roll isolation in this case. This is primarily because of two reasons. Ideally, the midline of teeth should coincide with midline of face and while restoring midline diastema, it becomes difficult to visualize the midline of face with the rubber dam in place [18]. Secondly, if the midline is shifted by 4 mm or less it is hardly perceptible to the naked eye, but if it is tilted mesio-distally by even 1° (i.e. canted midline), it is discernible. In the authors’ opinion, without rubber dam, it is easy to

circumvent both the above problems. On the other hand, this step in no way should compromise the longevity of the restoration. A follow-up after 14 months shows no evidence of discolorations, fractures, debonding or sensitivities (Fig. 10). Although a 14-month follow-up might not seem long enough, but the above mentioned restoration related failures generally manifest within 6 months after treatment [5]. Diastema closure only under cotton-roll isolation has been demonstrated previously as well [8].

CONCLUSION

By taking the past and current literature into consideration, an experienced clinician with the required skill, proper technique and case selection can create aesthetic and long-lasting direct resin composite restorations much to the satisfaction of his patients as with the case presented in this report. Diastema closure with correct anatomic contouring is easy to perform using the contoured sectional matrices.

References

1. Keene HJ. Distribution of diastemas in the dentition of man. *Am J Phys Anthropol* 1963;21:4: 437-41.
2. Kaimenyi JT. Occurrence of midline diastema and frenum attachments amongst school children in Nairobi, Kenya. *Ind J Dent Res* 1998;9:2:67-71.
3. Huang WJ, Creath CJ. The midline diastema: a review of its etiology and treatment. *Pediatr Dent* 1995; 17(3):171-9.
4. Ardu S, Krejci I. Biomimetic direct composite stratification technique for the restoration of anterior teeth. *Quintessence Int* 2006; 37: 167-74.
5. Korkut B, Yanikoglu F and Tagtekin D. Direct Midline Diastema Closure with Composite Layering Technique: A One-Year Follow-Up. *Case Reports in Dentistry* 2016. doi:10.1155/2016/6810984
6. Bağış B and Bağış HY. Porselen laminate veneerlerin klinik uygulama aşmaları: klinik bir olgu sunumu. *Ankara Üniversitesi Diş Hekimliği Fakültesi Dergisi* 2006; 33(1): 49- 57.
7. Hickel R, Heidemann D, Staehle HJ, Minnig P, and Wilson NH. Direct composite restorations: extended use in anterior and posterior situations. *Clin Oral Invest* 2004; 8(2): 43-4.
8. Margeas B. Free Hand Diastema Closure. *Oral Health* 2014 (April issue).
9. Ryge G. Clinical criteria. *Int Dent J* 1980;30:347-58.
10. Magne P and Belser UC. Porcelain versus composite inlays/onlays: effects of mechanical loads on stress distribution, adhesion, and crown flexure. *Int J Periodon Rest Dent* 2003;23(6): 543-55.
11. Berksun S, Kedici PS, and Sağlam S. Repair of fractured porcelain restorations with composite bonded porcelain laminate contours. *J Prosthet Dent* 1993; 69(5): 457-58.
12. Garber DA, Goldstein RE, and Feinman RA. *Porcelain Laminate Veneers*, Quintessence Publishing, Chicago, Ill, USA, 1988.
13. Jordan RE. *Esthetic Composite Bonding Techniques and Materials*, Mosby-Year Book, St. Louis, Mo, USA, 2nd edition, 1993.
14. Ardu S, Krejci I. Biomimetic direct composite stratification technique for the restoration of anterior teeth. *Quintessence Int* 2006; 37: 167-74.
15. Lenhard M. Closing diastemas with resin composite restorations. *Eur J Esthet Dent* 2008;3:258-68.
16. De Araujo EM Jr, Fortkamp S, Baratieri LN. Closure of diastema and gingival recontouring using direct adhesive restorations: a case report. *J Esthet Restor Dent* 2009;21: 229-40.
17. The Palodent® System. Instruction manual (Dentsply).
18. Brisman AS. Esthetics: a comparison of dentists' and patients' concepts. *J Am Dent Assoc* 1980;100:345-52.

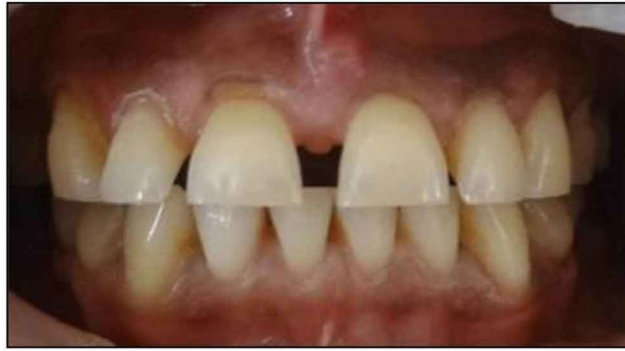

Fig. 1: Preoperative intraoral view of the patient shows interdental spacing in maxillary anteriors

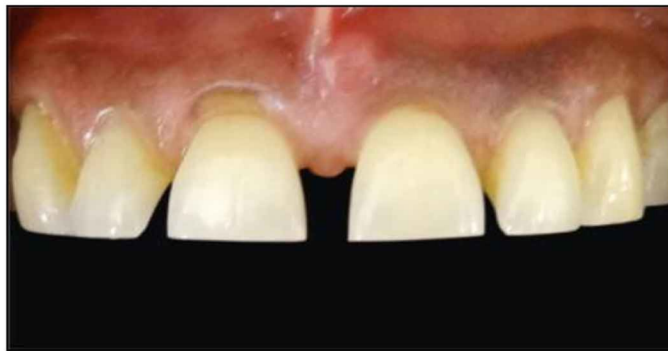

Fig. 2: Preoperative intraoral view of maxillary anteriors

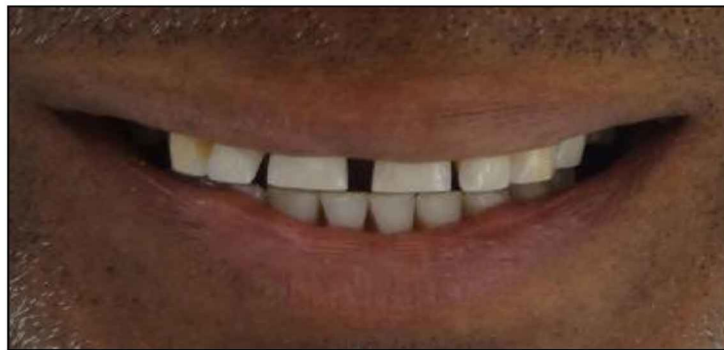

Fig. 3: Preoperative extraoral view of the patient

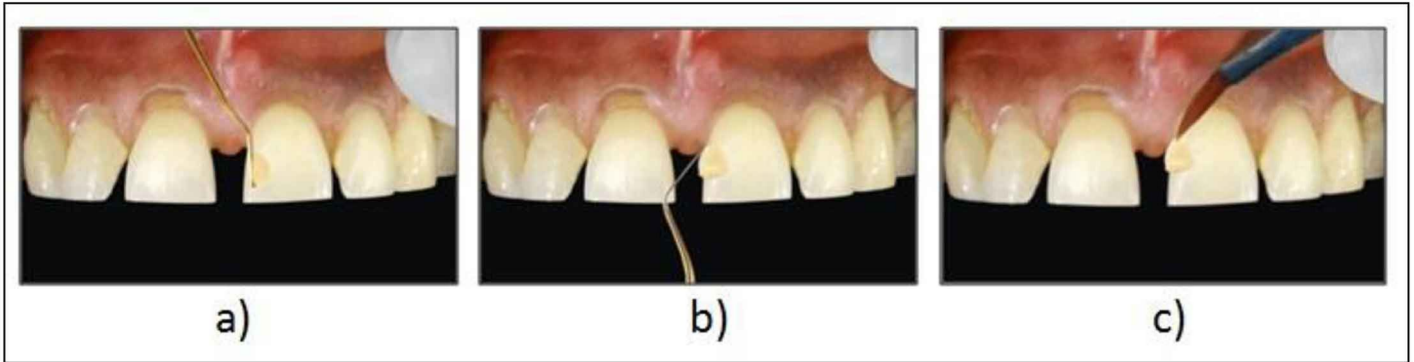


Fig. 4a) A small increment of composite is taken

Fig. 4b) This increment is flattened with the instrument and is sculpted towards free gingival margin

Fig. 4c) Composite is then thinned with a brush to achieve an imperceptible margin

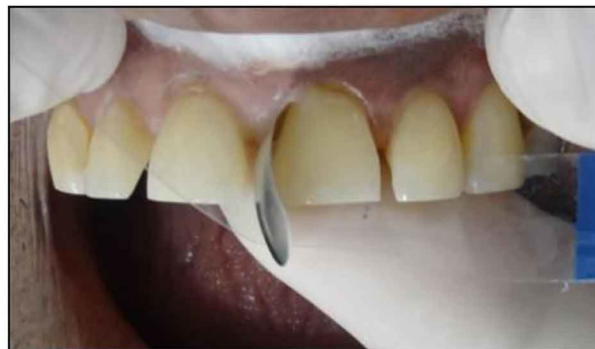

Fig. 5: Palodent® matrix and mylar strip was applied for restoration of 21

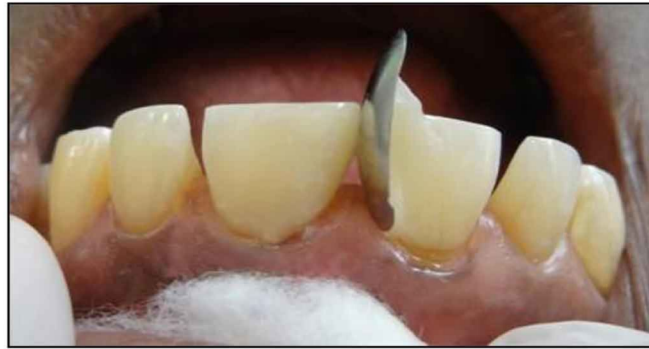

Fig. 6: Restoration of 11- matrix should be inserted slightly into the sulcus for correct emergence profile of the composite

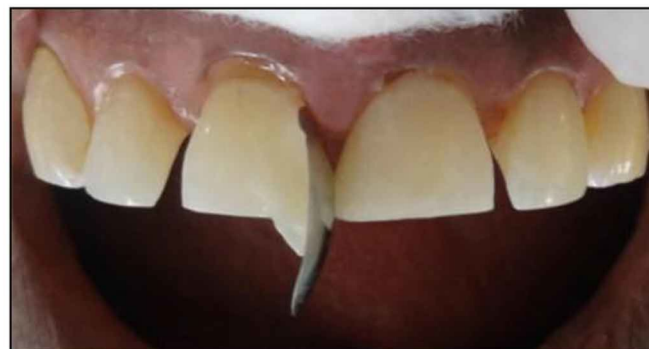

Fig. 7: Anatomic contours can be easily achieved using the contoured matrix

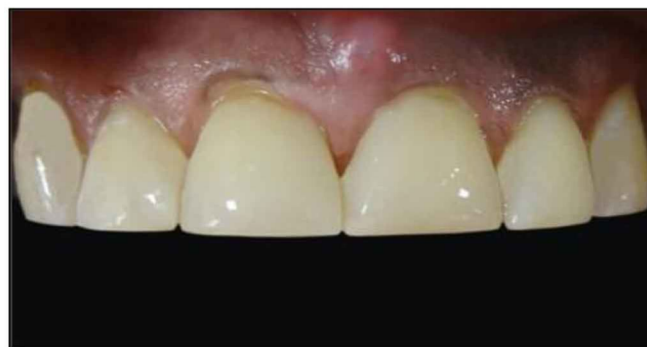

Fig. 8: Labial view of upper anteriors after diastema closure

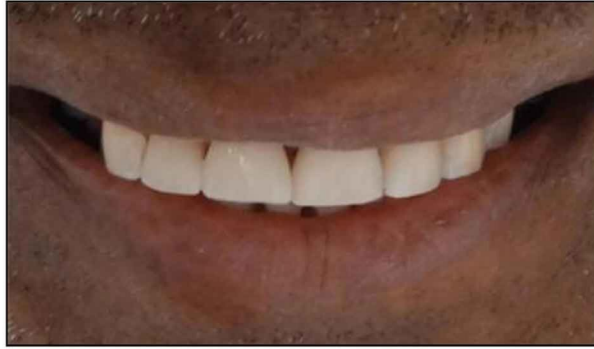

Fig. 9: Postoperative extraoral view of the patient

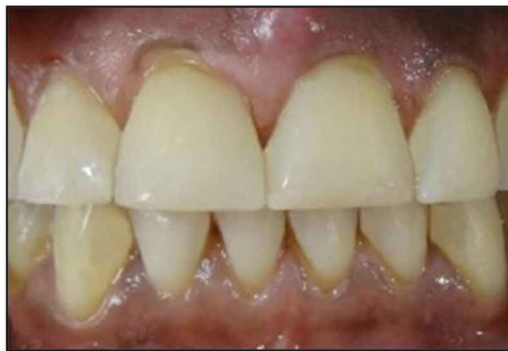

Fig. 10: View of the restorations at 14-month recall