



## Case of the Month – May 2017

### CASE REPORT

**TITLE: Surgical Removal of Separated Endodontic Instrument in the Periapex of Maxillary First Premolar - A case report**

**Authors:** Dr. Ritu Rana<sup>1</sup>, Dr. Uday Kumar<sup>2</sup>, Dr. Mamta Kaushik<sup>3</sup>, Dr. Prateeksha Chowdhry<sup>4</sup>

**Corresponding author** – Dr. Ritu Rana, Postgraduate Student, Department of Conservative Dentistry and Endodontics, Army College of Dental Sciences, CRPF Road, Chennapur, Jai Jawahar Nagar Post, Secunderabad, Telangana 500087, India, Ph: 9908728420, e-mail: riturana2013@gmail.com

**Dr. Uday Kumar-** Postgraduate Student, e-mail: uday0624355@gmail.com.

**Dr. Mamta Kaushik** – MDS (Professor and Head of the department), e-mail: mamkaushik@gmail.com

**Dr. Prateeksha Chowdhry-** Postgraduate Student, e-mail: ginnzz@gmail.com



## Case of the Month – May 2017

### **Abstract**

The unique morphology of dilacerated root canals often pose utmost challenges in their endodontic management. Common causes of failures in such cases are primarily related to procedural errors such as fractured instruments, ledges, canal blockages, zip and elbow creations. To achieve a successful treatment outcome, a clinician should have complete knowledge of internal anatomic relationships, do careful interpretation of radiographs and proper access preparation.

**Key words:** Dilacerated root, separated instrument, periapical surgery.



## Case of the Month – May 2017

### **Introduction**

A tooth with a straight root and a straight root canal is an exception rather than rule. Most teeth exhibit some curvature of the root canals and have multiple planes of curvature throughout their length <sup>[1]</sup>. Root dilaceration is one of the variations that may complicate the endodontic therapy.

The term dilacerations refers to an abrupt change in the axial inclination or curve in the crown or root of a tooth. It can also be defined as deviation of the apical part of the root by 20 degree or more <sup>[2]</sup>. The exact etiology of dilacerations is still controversial but the most accepted cause is mechanical trauma to the predecessor tooth <sup>[3-6]</sup>. The prevalence of dilacerations ranges from 0.32% to 7% <sup>[7]</sup>. The recognition and diagnosis of dilacerations are essential for any tooth that requires root canal therapy. In some cases, especially in dilacerated tooth the radiographic apex does not coincide with the anatomic apex of the tooth. In most of the cases (50-98% of all roots) the foramen deviate from the long axis of the tooth. So, Positioning the file at the radiological apex will often lead to under- or overinstrumentation. Microscopic studies have shown that the apical constriction to be located 0.5-1.0 mm from the major foramen <sup>[8-9]</sup>. The foramen does not coincide with the anatomical apex. It might be located laterally and in a distance of up to 3 mm from the anatomical apex <sup>[10]</sup>. Therefore, continuous monitoring of the working length may help clinicians to prevent the procedural errors like loss of reference point and over instrumentation especially in dilacerated roots.

The maxillary first premolars present variation in number of roots, canal configuration, the direction and longitudinal depressions of the roots, and various pulp cavity configurations <sup>[11]</sup>. Hence, they are among the most difficult teeth to be treated endodontically <sup>[12]</sup>.



## Case of the Month – May 2017

The prevalence of one root in these teeth varied from 15.5 to 60%<sup>[11-12]</sup>; two roots, 40-80.9%; and three roots, 0-9.2%<sup>[13]</sup>. The canal morphology of the maxillary first premolar teeth has been found with varying prevalence rates: One canal, 0-26.2%; two canals, 73.3-97%; and three canals, 0.5-9.2%<sup>[11-14]</sup>. Thus, it is evident that the anatomy of these teeth tends to have variations.

A frequent error that may occur during endodontic procedure in dilacerated root is the failure to maintain root canal curvature, resulting in ledge formation, apical transportation, zipping, perforation, and instrument breakage. Of the procedural errors, fracture of instrument has been discussed in the present case.

Prevalence of separated instruments ranges from 0.5% to 5%<sup>[15-18]</sup>. Failure in retrieval of the fractured instrument does not always result in failure of the case. However, the prognosis of the cases with fractured instruments depends on several factors such as: instrument size, the position of the instrument in the canal, type of material and canal anatomy.

	Success rate	Influence of fractured files on outcomes of endodontic treatment
<i>Strindberg</i> <sup>8</sup>	73%	Reduction of 19%
<i>Engström et al</i>	67%	No effect
<i>Engström and Lundberg</i>	100%	No effect
<i>Grossman</i> <sup>19</sup>	77%	Reduction in the success rate if periapical lesion
<i>Krump and Natkin</i> <sup>20</sup>	91%	No effect
<i>Fox et al</i>	93%	Reduction in the success rate if periapical lesion
<i>Kerekes and Tronstad</i>	82%	Reduction in the success rate on tooth necrosed
<i>Molyvdas et al</i>	87%	Reduction in the success rate if periapical lesion

Table-1: Influence on the success rate reviewed in the literature

Above mentioned studies have shown that the presence of a fractured instrument has little influence on success rates [Table-1]. According to Grossman<sup>[19]</sup> and Crump & Natkin<sup>[20]</sup>, the prognosis of teeth



## Case of the Month – May 2017

with remaining fragments mainly depends on the preoperative condition of the periapical tissue. This suggests that the nature of the problem lies with the presence of infection rather than the fractured instrument. If the broken file impedes adequate cleaning of the canal beyond the obstruction, prognosis might be adversely affected<sup>[21]</sup>. Therefore, the best option in such cases is removal of fractured instrument<sup>[22]</sup>. However, when no pre-operative pathological changes are recognized, and orthograde removal has been attempted without success, the fractured fragment should be left in the root canal, intentionally<sup>[23]</sup>. Ingle & Beveridge<sup>[24]</sup> have also shown that less than 1% of endodontic failures result from broken instruments.

In rare cases, if the endodontic instrument separates beyond the apical foramen, it should be surgically removed. The fractured segment is a foreign object and is always accompanied with bacteria and dentinal debris that may cause inflammation<sup>[25-26]</sup>. Moreover, it affects the psychological well-being of the patient. However, the precise position and size of the fractured instrument as well as its relation to the root apex and surrounding anatomic structures should be understood before attempting surgical retrieval of the fractured segment<sup>[27]</sup>.

The purpose of this case report was to present the surgical removal of a broken endodontic file from the palatal root of a maxillary first premolar.

### **Case report**

A 48 year old female patient was reported to the Department of Conservative Dentistry and Endodontics, Army College of Dental Sciences, with a chief complaint of pus discharge from the right upper back region of the jaw since the past 15 to 20 days.

Medical and family histories were noncontributory. Intraoral examination revealed a localized erythematous area of inflammation and sinus opening with pus discharge at the root apex of tooth #14. Severe cervical abrasion exposing the canal of tooth #14 was seen. Periodontal probing revealed a normal intact gingiva. On pulp status evaluation, the tooth showed no response with heat, cold and electric pulp tests. The pre-operative radiograph showed a coronal radiolucency involving



## Case of the Month – May 2017

the pulp [Figure 1] with small ill-defined periapical radiolucency w.r.t # 14. A diagnostic radiograph was taken after the insertion of a gutta-percha cone (# 25; 2%) into the sinus tract [Figure 2], confirming the diagnosis of chronic alveolar abscess with respect to tooth #14. After careful reading of radiograph, presence of dilacerations was seen in apical part of root. Root canal therapy was advised for the maxillary right first premolar (tooth 14).

Access cavity was prepared using round carbide bur under rubber dam isolation. By keeping the radiograph as a reference, #15 k-file was precurved to the curvature of roots of first premolar. This glide path was ascertained till radiographic working length (WL). Coronal flaring was achieved by using size 1-4 Gate-glidden drills sequentially in a step-back technique.

Sequential filing of the curved canals was done using nickel titanium (NiTi) hand files No. 15, 20, and 25 (Mani, Inc, Japan) till the working length. Special emphasis was placed on frequent irrigation of the root canal and recapitulation was done to avoid blockage by dentinal debris. Irrigation during instrumentation was carried out using 2.5% sodium hypochlorite, 17% EDTA and saline. Final cleaning and shaping was carried out using Protapers rotary files (Dentsply Maillefer, Ballaigues, Switzerland) with a 64:1 reduction gear Rotary endodontic hand piece. In the process of cleaning and shaping, a 4.5 mm segment of F2 rotary protaper got fractured, 2/3rd of which laid inside the canal and the rest extending into the periapex [Figure 3].

The patient was informed regarding the mishap. The tooth was temporized and kept under observation for a week. During the recall visit, the patient gave a positive history for pain on mastication and a decision was made to remove the fractured instrument, surgically.

### **Pre-operative preparations**

The IOPA was taken to measure: (1) The approximate size of the fractured instrument, (2) the distance from the reference point (buccal cusp) to the apex of the tooth.



## Case of the Month – May 2017

### Procedure

An informed consent was taken from the patient. The procedure was performed under local anesthesia 2% lignocaine with 1:80,000 adrenaline. A crevicular incision was given from the mesial aspect of the maxillary right canine till the mesial aspect of the maxillary right first molar and a mesial releasing incision extending into the vestibule was taken to raise a triangular flap. Sub-periosteal reflection was done. A 5 mm bony window [Figure 4] was prepared through the buccal cortex corresponding to the buccal root apex of the premolar at the previously calculated length (IOPA). The instrument was carefully visualized [Figure 5] and observed to be exiting at the buccal surface 3mm short of the anatomic apex. It was then removed with a mosquito forceps. Postoperative radiographs were taken to ensure complete removal of the separated instrument. The wound was then curetted, and irrigation was done with betadine. The canals are irrigated using saline, dried and obturated [Figure 6]. The root end cavity was prepared using micromotor handpiece and MTA was applied as root end filling material [Figure 7]. The gingival flap was replaced and sutured.

Patient was prescribed Augmentin 625 mg T.D.S, Metrogyl 400 mg T.D.S, Accecloran T.D.S for 5 days and 0.12% chlorhexidine gluconate mouthwash twice a day for 7 days. After 7 days, the patient was recalled for suture removal and post-endodontic restoration with composite was done [Figure 8].

Periodic evaluation was done after 3 months [Figure 9], 6 months [Figure 10]. The patient was asymptomatic. Radiographically, there was reduction of size of periapical radiolucency.

### Discussion

The fracture of endodontic instruments is one of the troublesome incidents within root canal. One should be able to handle these errors, so as to give the best possible treatment to the patient. When an instrument fractures during root canal preparation, there are four basic approaches to deal with the problem: (i) Removing (ii) Bypassing and sealing it within the root canal; or (iii) Blocking the root canal with it (iv) Surgery. But, there is no specific technique to remove separated endodontic instruments



## Case of the Month – May 2017

from the root canal. Some of these techniques include: ultrasonic, endodontic forceps, endodontic files, hollow tube-based extractor systems<sup>[28-30]</sup>.

For retrieving the fractured instrument, the most important factor to be considered is its location and its relationship with the curvature of the canal. When the fragment is positioned coronally to the curvature of the canal, the possibility of removing the fragment is increased. Whereas, when the fragment is situated at or beyond the curvature of the canal the possibility of its retrieval will be reduced or impossible<sup>[31-33]</sup>.

The removal of a separated instrument particularly located in the apical third of the root canal is complex. Attempts to do so using the above mentioned techniques can increase the risks of ledge formation, root perforation, and root fracture<sup>[34-35]</sup>.

In the present case, the fractured instrument was beyond the apical foramen. So, it was surgically removed without causing any damage to the internal tooth structure.

Before attempting surgical removal, thorough history, clinical examination, and good quality periapical radiographs are required<sup>[36]</sup>. Conventionally radiographs are being used despite certain drawbacks like magnification and overlapping of images, difficulty in film placement and most of all the identification of the exact foramina in a resorbing root<sup>[37]</sup>. However, they are essential for pre-operative diagnosis of the tooth involved and also to assess the technical difficulty in retrieving the fractured segment. Since, maxillary premolars are in close association to the maxillary sinus, therefore in the present case, IOPA are taken to visualize its proximity to this anatomical landmark.

One of the critical steps in endodontic treatment is working length determination. In the present case, Radiographic method alone was used to determine working length. As a result, over instrumentation was done causing breakage of instrument beyond the apical foramen. To achieve accuracy in working length determination, an apex locator should also be used. Apex locators are one of the breakthroughs that brought electronic science into the conventional endodontic practice. These helps





## Case of the Month – May 2017

in limiting instrumentation within the confines of root canal system, especially in dilacerated root. Studies done on permanent teeth have shown more than 80% accuracy with electronic apex locators<sup>[38-39]</sup>. They are found to be accurate in the presence of canal contents, irrigating solutions, detection of perforations and also apical root resorptions<sup>[40-41]</sup>. These operate on the basis of electrical impedance rather than visual inspection<sup>[42]</sup>. Modern apex locators are capable to determine an area between the minor and major apical foramina, determining the impedance between the file tip and the canal with different frequencies<sup>[43]</sup>.

To avoid these procedural errors, the basic principles of endodontic therapy should be followed, that is good preoperative radiograph, straight line access to apical foramen, pre-curving the endodontic hand instrument, file recapitulation, thorough irrigation and use of flexible Ni- Ti instruments<sup>[44-45]</sup>. Hence, in the present case all these principles were followed. Even though the root canal ended sooner but the instrumentation which was done till the radiographic apex resulted in breakage of instrument beyond the apical foramen.

In the present case, Mineral trioxide aggregate (MTA) has been used as an root end filling material before obturation, because of its high biocompatibility, excellent sealing ability, good performance in presence of moisture and induction of formation of hard tissue barrier.

This paper describes a case report in which a file was separated beyond apical foramen and removed from the palatal root canal of a maxillary first premolar using surgical approach.

**Conclusion-** Precise location of the fractured segment was predicted and retrieved using modern techniques, following which the tooth was successfully treated without any complication.

### **References**

1. Cohen S, Burns RC. Pathways of the pulp. 8th ed, St Louis: Mosby; 2002.
2. Jafarzadeh H, Abbott PV. Dilaceration: review of an endodontic challenge. J Endod. 2007;33:1025–30



## Case of the Month – May 2017

3. Maragakis MG. Crown dilaceration of permanent incisors following trauma to their primary predecessors. *J Clin Pediatr Dent.* 1995; 20:49-52.
4. Kearns HP. Dilacerated incisors and congenitally displaced incisors: three case reports. *Dental Update.* 1998; 25:339-42.
5. Matsuoka T, Sobue S, Ooshima T. Crown dilaceration of a first premolar caused by extraction of its deciduous predecessor: a case report. *Endod Dent Traumatol.* 2000; 16:91-4.
6. Prabhakar AR, Reddy VV, Bassappa N. Duplication and dilacerations of a crown with hypercementosis of the root following trauma: a case report. *Quintessence Int.* 1998; 29:655-7
7. Stewart DJ. Dilacerated unerupted maxillary central incisors. *Br Dent J.* 1978; 145:229-33.
8. Kuttler Y. Microscopic investigation of root apexes. *J Am Dent Assoc.* 1955;50:544–52
9. Martinez-Lozano MA, Forner-Navarro L, Sanchez-Cortex JL, Llena-Puy. Methodological considerations in the determination of working length. *Int Endod J* 2001;34:371-76.
10. Dummer PM, McGinn JH, Rees DG. The position and topography of the apical canal constriction and apical foramen. *Int Endod J.* 1984;17:192–8
11. Hamasha AA, Al Khateeb T, Darwazeh A. Prevalence of dilaceration in Jordanian adults. *IntEndod J.* 2002; 35:910-2.
12. Pecora JD, Saquy PC, Sousa Neto ND, Woelfel JB. Root form and canal anatomy of maxillary first premolars. *Braz Dent J.* 1992;2:87–94
13. Loh HS. Root morphology of maxillary first premolar in Singaporeans. *Aust Dent J.* 1998;43:399–402.
14. Lipski M, Woźniak K, Łagocka R, Tomasik M. Root and canal morphology of the first human maxillary premolar. *Durham Anthropol J.* 2003;12:2–3.
15. Pineda F, Kuttler Y. Mesiodistal and buccolingual roentogenic investigations of 7,275 root canals. *Oral Surg.* 1972;33:101–10
16. Spili P, Parashos P, Messer HH. The impact of instrument fracture on outcome of endodontic treatment. *J Endod.* 2005; 31:845–50.



## Case of the Month – May 2017

17. Knowles KI, Hammond NB, Biggs SG, Ibarrola JL. Incidence of instrument separation using LightSpeed rotary instruments. *J Endod.* 2006; 32:14–6.
18. Wolcott S, Wolcott J, Ishley D, Kennedy W, Johnson S, Minnich S, et al. Separation incidence of protaper rotary instruments: A large cohort clinical evaluation. *J Endod.* 2006; 32:1139–41.
19. Iqbal MK, Kohli MR, Kim JS. A retrospective clinical study of incidence of root canal instrument separation in an endodontics graduate program: A PennEndo database study. *J Endod.* 2006; 32:1048–52.
20. Grossman LI. Fate of endodontically treated teeth with fractured root canal instruments. *J Br Endod SOC* 1968;2:35-7.
21. Crurnp MC, Natkin E. Relationship of broken root canal instruments to endodontic case prognosis: a clinical investigation. *J Am Dent Assoc* 1970;80:1341-7.
22. Fors UG, Berg JO. A method for the removal of broken endodontic instruments from root canals. *J Endod.* 1983; 9:156–9.
23. Machtou P, Reit C. Non-surgical retreatment. In: *Textbook of Endodontology*. 1st ed. Oxford: Blackwell Munksgaard Ltd; 2003.
24. Hülsmann M, Schinkel I. Influence of several factors on the success or failure of removal of fractured instruments from the root canal. *Endod Dent Traumatol.* 1999; 15:252–8.
25. Ingle JI, Beveridge EE, *Endodontics*. 2nd ed. Philadelphia: Lea & Febiger; 1976.
26. Kaufman A, Neuman H. Iatrogenic damages caused by dental procedures. Foreign bodies in the oral cavity. *Quintessence Int Dent Dig.* 1983; 14:361–6.
27. Lin LM, Rosenberg PA, Lin J. Do procedural errors cause endodontic treatment failure? *J Am Dent Assoc.* 2005; 136:187–93.
28. Wang H, Ni L, Yu C, Shi L, Qin R. Utilizing spiral computerized tomography during the removal of a fractured endodontic instrument lying beyond the apical foramen. *Int Endod J.* 2010; 43:1143–51.



## Case of the Month – May 2017

29. Nagai O, Tani N, Kayaba Y, Kodama S, Osada T. Ultrasonic removal of broken instruments in root canals. *Int Endod J.* 1986;19:298–304.
30. Suter B, Lussi A, Sequeira P. Probability of removing fractured instrument from root canals. *Int Endod J.* 2005;38:112–123.
31. Ruddle CJ. Micro-endodontic nonsurgical retreatment. *Dent Clin North Am.* 1997;41:429–454.
32. Ward JR, Parashos P, Messer HH. Evaluation of an ultrasonic technique to remove fractured rotary nickeltitanium endodontic instruments from root canals: an experimental study. *J Endod.* 2003;29:756–763.
33. Ruddle CJ. Nonsurgical retreatment. In: Cohen S, Burns RC, editors. *Pathways of the pulp.* 8th ed. St Louis: CV Mosby Co; 2002.
34. Ruddle C. Nonsurgical retreatment. *J Endod.* 2004;30:827–845.
35. Parashos P, Messer HH. Rotary NiTi instrument fracture and its consequences. *J Endod.* 2006;32:1031-1043.
36. Madarati AA, Qualtrough AJ, Watts DC. Vertical fracture resistance of roots after ultrasonic removal of fractured instruments. *Int Endod J.* 2010;43:424-429.
37. Reit C, Petersson K, Molven O. *Textbook of Endodontology.* 1st ed. Oxford, UK: Blackwell Publishing Ltd; 2003.
38. Mente J, Seidel J, Buchalla W, Koch MJ. Electronic determination of root canal length in primary teeth with and without root resorption. *Int Endod J.* 2002;35:447-52
39. Shabahang S, Goon WW, Gluskin AH. An in vivo evaluation of Root ZX electronic apex locator. *J Endod* 1996; 22:616-8.
40. Pratten DH, McDonald NJ. Comparison of radiographic and electronic working lengths. *J Endod.* 1996;22:173-6.
41. Pagavino G, Diamante D, Marri M, Pace R. Localization of the apical foramen using the newest electronic instruments: Stereomicroscopy and SEM. *Minerva Stomatol.* 1995;44:499-506.



## Case of the Month – May 2017

42. Kaufman AY, Fuss Z, Keila S, Waxenberg S. Reliability of different electronic apex locators to detect root perforations in vitro. *Int Endod J.* 1997;30:403-7.
43. Kim E, Lee SJ. Electronic apex locator. *Dent Clin North Am.* 2004;48:35-54.
44. Dastmalchi N, Kazemi Z, Hashemi S, Peters OA, Jafarzadeh H. Definition and endodontic treatment of dilacerated canals: a survey of Diplomates of the American Board of Endodontics. *J Contemp Dent Pract.* 2011; 12:8-13.
45. Jafarzadeh H, Abott PV. Dilaceration: review of an endodontic challenge. *J Endod.* 2007; 33(9):1025-30.

## **FIGURES**

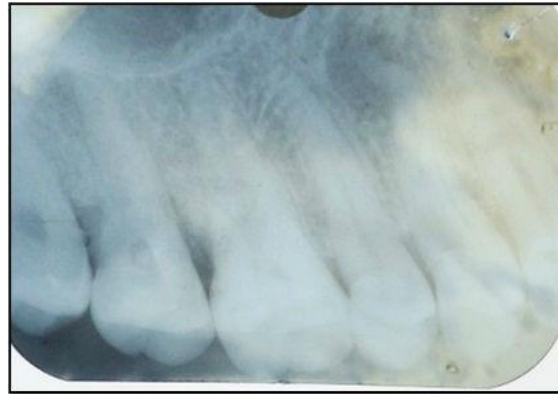

Figure- 1: Pre-operative radiograph

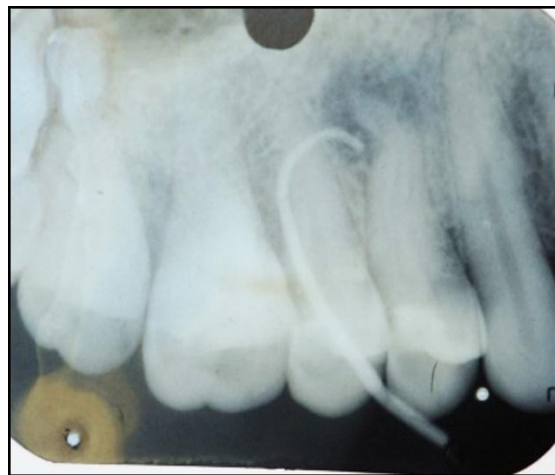


Figure-2: Radiograph showing sinus tract tracing using GP

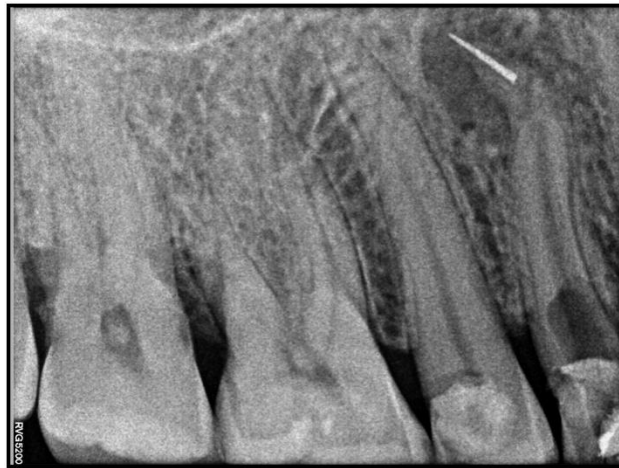

Figure-3: Radiograph showing fractured instrument beyond apex

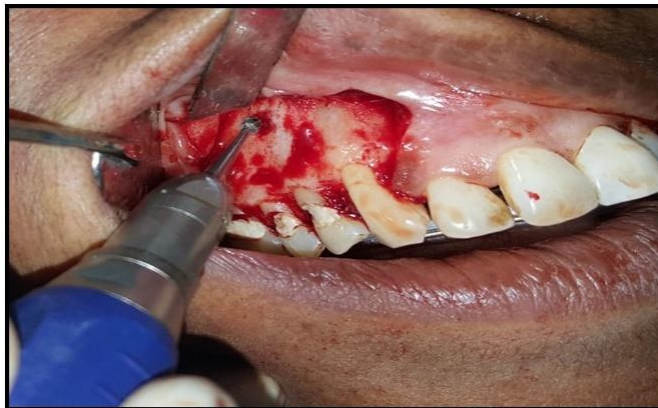

Fig-4: Bone cutting using micromotor handpiece

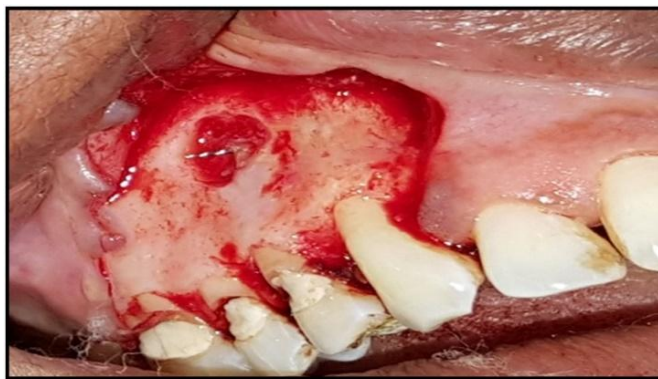



Fig-5: Fractured instrument beyond apex

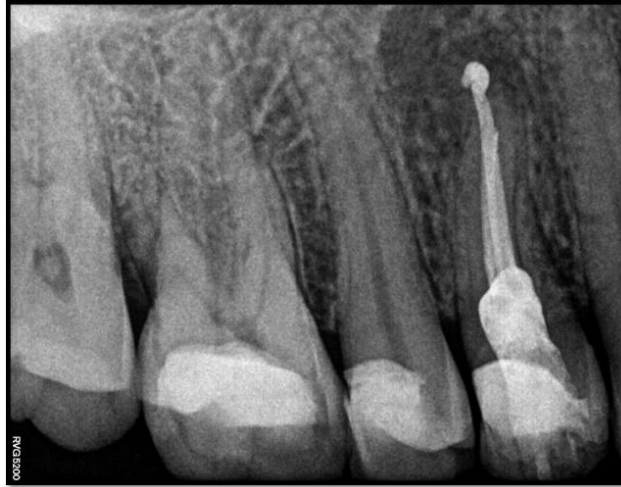

Fig-6: Post-obturation radiograph

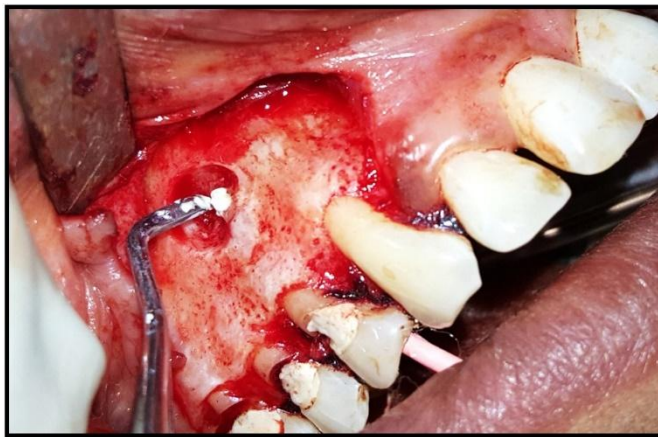
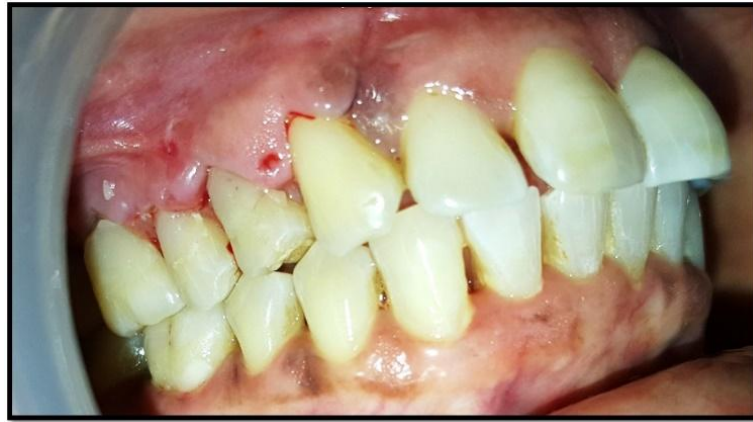
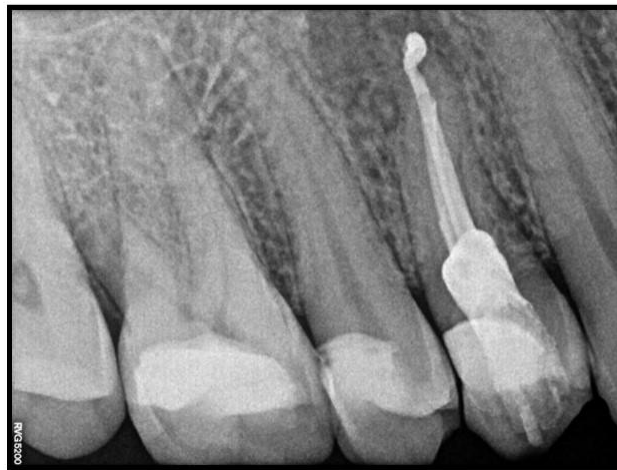
Fig-7: MTA placement





**Fig-8: Post-operative view**



**Fig-9: 3 months follow up**

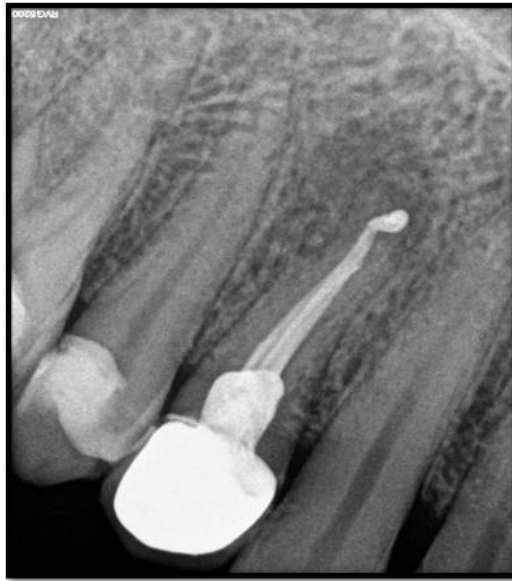

Fig-10: 6 months follow up