

Management of a Type II variant of Dens Invaginatus with periapical radiolucency

Authors: (Dr. R. Ahmed Dental College and Hospital)

Amrita (IIIrd Year PGT)

Dr. H.D. Adhikari (Prof. and HOD)

Dr. Mohan Lal Paul (Prof.)

Abstract :

Dens Invaginatus is an anomaly of the tooth formation of embryonic origin that presents itself in several morphologic types. The complex anatomy of these teeth makes nonsurgical endodontic treatment complex and more so when its apex is immature. The case reported illustrates the nonsurgical endodontic management of a Dens Invaginatus type II and periapical lesion using a Biodentine® (Septodont). A 14-month follow-up of the case shows a complete periapical healing with bone formation at the site of the lesion.

Introduction:

Dens Invaginatus has been defined as a defect in tooth development, characterized by invagination of the enamel organ before the calcification phase.¹ Other names for this type of malformation are Dens in Dente, Invaginated Odontoma, and Dentoid In Dente. The etiology is still unclear and controversial and several theories have been suggested, including alterations in tissue pressure, trauma, infection, or local discrepancy in the cellular hyperplasia.

It has been **classified** into the following **3 types** according to the depth of the invagination and the degree of communication with the periodontal ligament or the periradicular tissue.²

1. **Type I:** Invagination confined inside the crown, not extending beyond the cemento-enamel junction (CEJ).
2. **Type II:** Invagination extending beyond the CEJ, it may or may not communicate with the pulp and not reach the periradicular tissue.
3. **Type III:** Invagination extending beyond the CEJ penetrating the root and exhibiting a second foramina in the apical third within the periradicular tissue.

Endodontic treatment of Dens Invaginatus type II and III can become complicated because of an unpredictable internal anatomy. In cases in which there is an immature apex, the use of calcium hydroxide and MTA have been proposed to obtain an apical closure. Biodentine® (Septodont) is a new calcium silicate based cement that can be used as another alternative. It has similar basic composition as MTA but a shorter setting time (9-12 minutes), making single visit apexification possible. Many authors have reported clinical success with the apical closure technique using Biodentine.³⁻⁴

This article presents a successful case of treatment of Dens Invaginatus type II with a diagnosis of pulp necrosis with periapical pathology using Biodentine®.

Case Report:

A female patient (age - 28 years) came to the Department Of Conservative Dentistry And Endodontics, Dr. R.Ahmed dental College and Hospital, Kolkata, with the chief complaint of chronic pain in the upper anterior region. She gave history of trauma 15 years back.

On examination, #21 showed an anomalous clinical crown, with a marked depression in the labial and palatal aspect. (Fig 1 & Fig. 2)

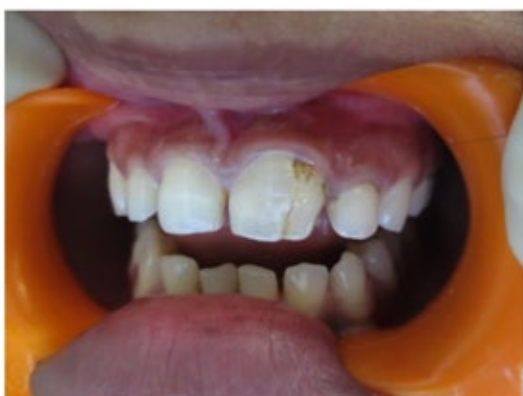

Fig 1. Labial aspect

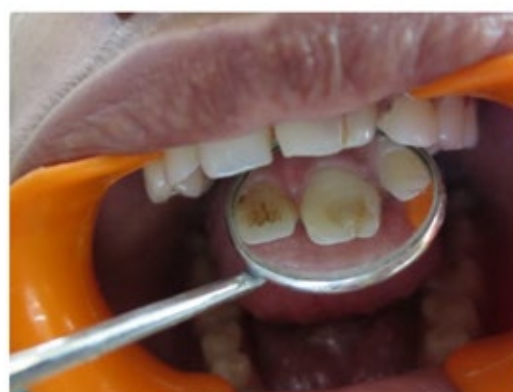

Fig 2. Palatal aspect

A periapical radiograph suggested the presence of a Dens Invaginatus type II, with immature apex in #21, associated with periapical pathology. (Fig 3). which was confirmed with Spiral CT (Quadra Medical and Diagnostic Center) (Fig. 4,5 & 6). Sensitivity tests to cold, heat and electric pulp test confirmed #21 to be non- vital.

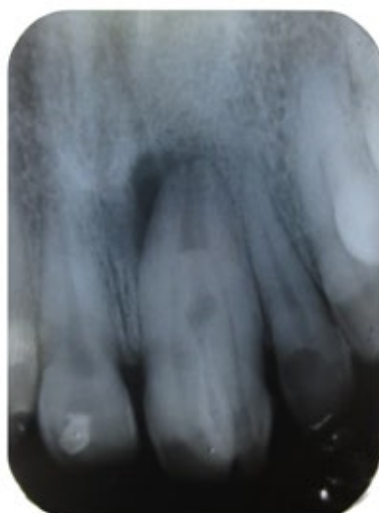

Fig. 3 Periapical radiograph suggesting Dens invaginatus- Type II

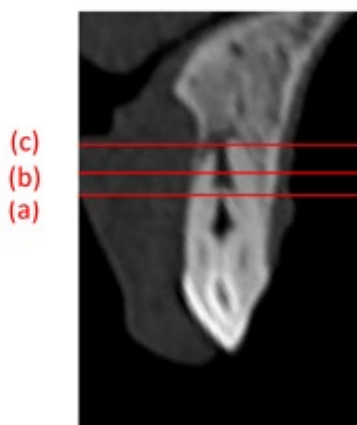


Fig. 4: Spiral CT- Sagittal section
(a),(b) & (c) - site of corresponding sections shown in Fig. 6

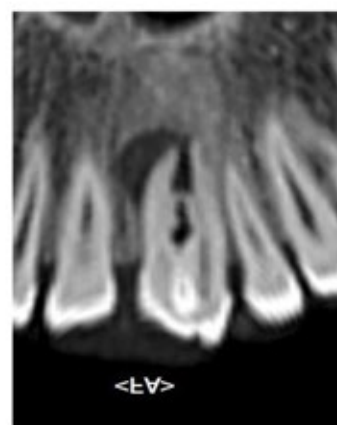

Fig. 5: Spiral CT- Coronal section

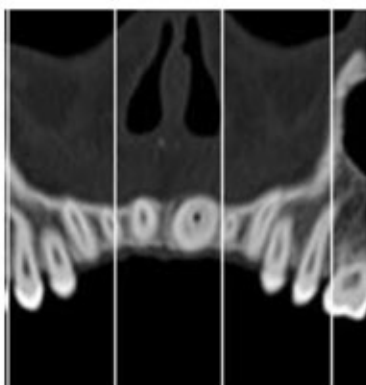


Fig. 6 (a)

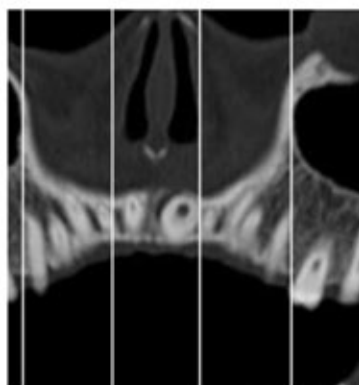


Fig. 6 (b)

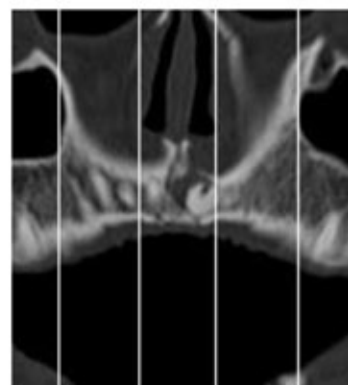


Fig 6 (c)

Fig 6: spiral CT - Axial Sections of apical 1/ 3rd.
 (a) showing tooth within the tooth,
 (b) showing communication of two pulp spaces,
 (c) showing single exit with open apex. } (corresponding sections at the levels shown in Fig. 4)

After application of Local anesthesia (Lidocaine 2% with epinephrine 1:80 000) and isolation of the operative field with rubber dam, an adequate endodontic access cavity was performed through the invagination with diamond burs #2.

After establishing working length, the canal was cleaned and shaped with #70 and # 80 K-files and H-files. Copious irrigation was carried out with 5.25% sodium hypochlorite. Calcium hydroxide was placed as medication inside the canal and sealed with cavit; the dressing was changed twice at an interval of 7 days. An apical barrier of 4 mm in thickness was created with Biodentine® (Septodont) and the canal was backfilled with thermoplasticised GP (Fig. 7). The access cavity was restored with composite resin. CBCT view (Myriad software- recently installed in Dr. RADC & H, Kolkata) after 14 months of treatment shows complete healing of the periradicular tissue (Fig. 8).

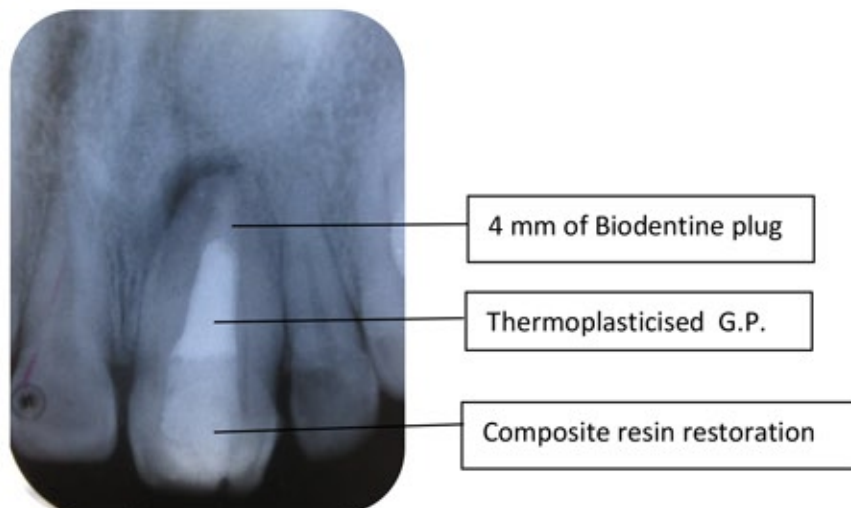


Fig. 7: Six month - Post Operative Radiograph

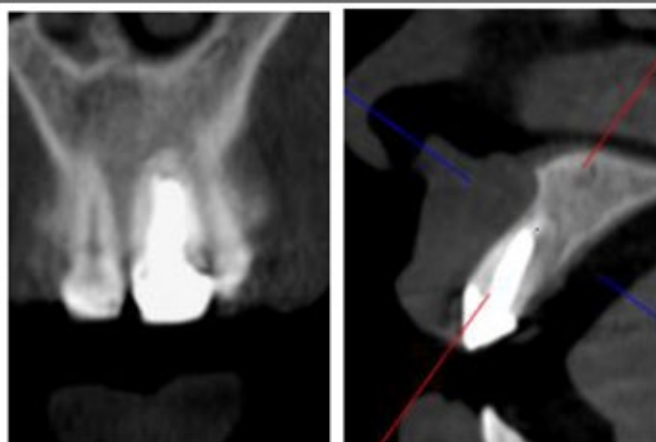


Fig. 8 : 14 month follow-up shows complete healing in CBCT – Coronal and Sagittal section

DISCUSSION:

Nonsurgical endodontic treatment in teeth with Dens Invaginatus should be the first treatment alternative before recurring to endodontic surgery, intentional replantation, or extraction of the tooth. However, endodontic treatment of dens invaginatus type II and III can become complicated because of an unpredictable internal anatomy. A complete **disinfection** of the canal is of great importance to promote healing of affected periradicular tissues. In this case, 5.25% sodium hypochlorite as irrigant and calcium hydroxide as intracanal medication between appointments were used to obtain this result.

Another problem encountered in this case was **open apex**. The treatment period with calcium hydroxide to obtain a biological apical closure is long and unpredictable, introducing concerns about intervisit contamination of the pulp space. Though MTA is advantageous in this regard, still at least two appointments are required to complete the treatment procedure due to its long setting time (2hr 45 min). Biodentine⁵ has a shorter setting time (9-12 min) making apexification alongwith restoration possible in single visit.

REFERENCES

1. Glossary of terms used in endodontics. 7th ed. Chicago: American Association of Endodontics; 2003.
2. Oehlers FA. Dens invaginatus. I. Variations of the invagination process and associated anterior crown forms. *Oral Surg Oral Med Oral Pathol* 1957;10:1204-18.
3. Nayak G, Hasan M F Biodentine- a novel dentinal substitute for single visit apexification *Rest Endo* 2014
4. Khetarpal A, Chaudhary S. Endodontic management of open apex using Biodentine as a novel apical matrix. *IJDR* 2003;19:165-9.
5. Septodont Biodentine scientific file 2010.